

Orbitofrontal sulcogyral pattern may help to differentiate schizophrenia and autism-spectrum disorder.

Goultchira Chakirova, Moorhead TWJ, Stanfield AÇ, Ruth Philip, Welch KA, Brown VJ, Hall J, Lawrie SM, Johnstone EC, McIntosh AM.

Division of Psychiatry, University of Edinburgh, Edinburgh, UK
 Contact: G.Chakirova@sms.ed.ac.uk



Introduction:

There is considerable evidence that the orbitofrontal cortex (OFC) plays a role in the pathophysiology of autism (Bachevalier, 2006; Dawson, 2002; Salmond, 2003), abnormalities of the structure likely being particularly important in the impaired social interactions so characteristic of the condition. Specifically, the right lateral subdivision is believed to be important in social cognition (O'Doherty, 2001; Vollm, 2006), and decreased grey matter volume has been reported in children with autism associated with social deficits (Girgis, 2007). Abnormal OFC connectivity has also been observed in autism, being reported in fronto-striatal, fronto-parietal pathways and the orbitofrontal-amygdala circuit (Bachevalier, 2006; Just, 2007; Silk, 2006). Abnormalities of orbitofrontal cortical folding pattern have previously been reported in patients with schizophrenia (Nakamura, 2007). We investigated if such abnormalities were also present in people with autism spectrum disorder.

Methods:

11 participants with autism spectrum disorder, 34 patients in their first episode of schizophrenia and 36 control had a sMRI scan of the brain.

Based on connectivity of three main orbital sulci (See Figure 1) orbitofrontal sulcogyral patterns were classified within each hemisphere into one of four types (Chiavaras, 2000; Chakirova et al., in press).

The rater was blinded to the participants' group membership. The intraclass correlation coefficients (Cronbach's α) of the method were 0.84 for the left hemisphere and 0.86 for the right hemisphere. Chi-square analysis was performed to compare the distribution of the sulcogyral patterns in the three groups.

Results:

Participants with autism had increased type II in the right hemisphere (See Figure 2) compared to healthy controls ($p = .016$) and patients with first episode schizophrenia ($p = .040$).

Expression of OFC type I and III differed significantly in first episode schizophrenia when compared to healthy individuals (See Figure 2). The distribution of type I expression was significantly reduced in the first episode schizophrenia group ($p = .034$). Type III expression was significantly increased in the same group ($p = .018$) especially on the right side ($p = .031$).

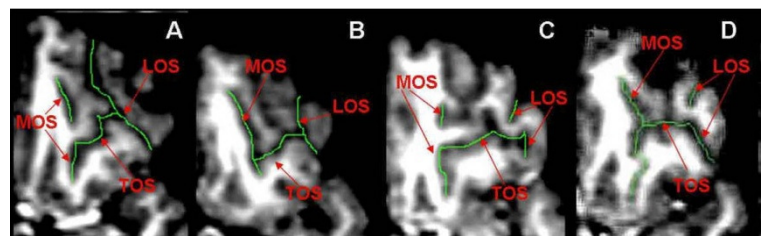
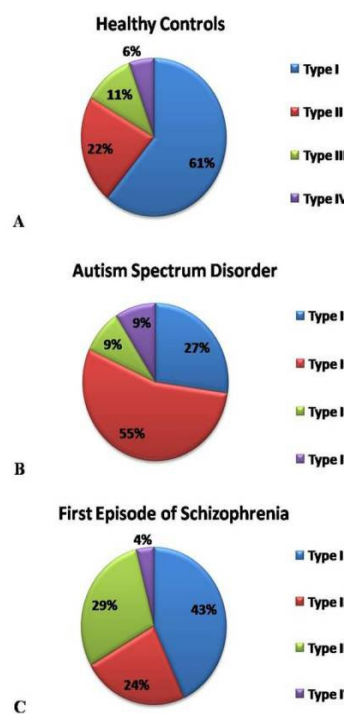


Figure 1. Examples of the main orbitofrontal sulcal patterns of the human brain on the left hemisphere from four different participants: A = Type I, B = Type II, C = Type III, D = Type IV. On the transverse view of MRIcro sulci were delineated with green colour. Main sulci of the OFC: LOS = Lateral Orbital Sulcus; MOS = Medial Orbital Sulcus; TOS = Transverse Orbital Sulcus (Chakirova et al., in press).

Right Hemisphere



Left Hemisphere

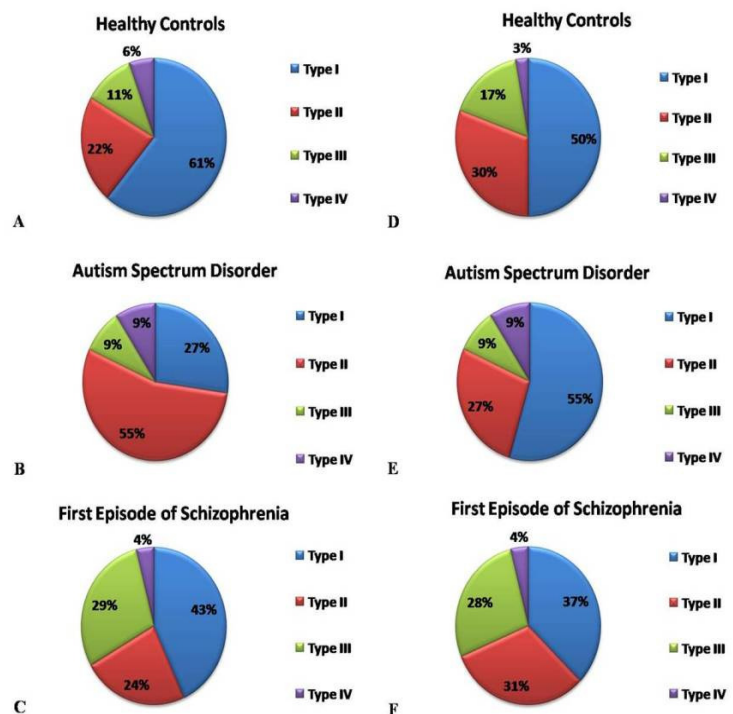


Figure 2. Distribution of orbitofrontal sulcogyral pattern in healthy controls, patients with first episode schizophrenia and ASD (autism-spectrum disorder): A, B, C = the right hemisphere. D, E, F = the left hemisphere. See Methods section and Figure 1 for the description of types I-IV.

Conclusions:

This is the first study to investigate orbitofrontal sulcogyral pattern distribution in people with autism spectrum disorder. OFC Type II is overexpressed in the right hemisphere of people with autism, conversely OFC Type III is overexpressed in the same region in schizophrenia. OFC typing may have some utility in differentiating the two conditions in cases posing diagnostic challenges. Additionally, observation of these differences provides a further rationale for focussing work aimed at identifying specific brain abnormalities of structure or function characteristic of autism in this region.



Acknowledgements:

This work was supported by the SINAPSE (Scottish Imaging Network – A Platform for Scientific Excellence) collaboration (www.sinapse.ac.uk). Professor Stephen M. Lawrie is supported by a NARSAD Senior Scientist Award. Dr. Jeremy Hall is funded by an MRC Clinical Research Training Fellowship. Dr. Andrew M. McIntosh is supported by the Health Foundation UK through a Clinician Scientist Fellowship. Financial support for the scans was provided by the Sackler Foundation.