

Introduction

Ultrasound elastography provides a colour map of tissue elasticity which is superimposed on the real-time greyscale ultrasound image. Invasive breast cancers have been shown to be stiffer than benign or normal tissues. Conventional elastography is qualitative and has been hampered by significant interobserver variability. Shear wave elastography is a new method of obtaining elastography images based on the combination of a radiation force induced in a tissue by an ultrasonic beam and an imaging sequence catching the resultant shear waves enabling the production of a map of shear elasticity. The technique is performed using a conventional linear array probe.

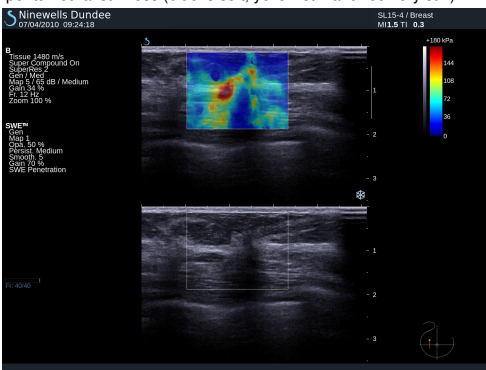
Within a given ROI, defined by an electronic cursor, values for the maximum stiffness, mean stiffness and standard deviation (SD) are produced. The published literature on shear wave elastography of the breast is almost non-existent. It is possible that the addition of shear wave elastography may increase the ability of breast ultrasound to differentiate between benign and malignant masses. The aims of our study were to determine the reproducibility of shear wave elastography findings, to correlate the elasticity values of a consecutive series of solid breast masses with percutaneous and surgical histology findings, and to investigate the accuracy of shear wave elastography compared with greyscale ultrasound with BI-RADS classification in distinguishing benign from malignant breast lesions.

Methods

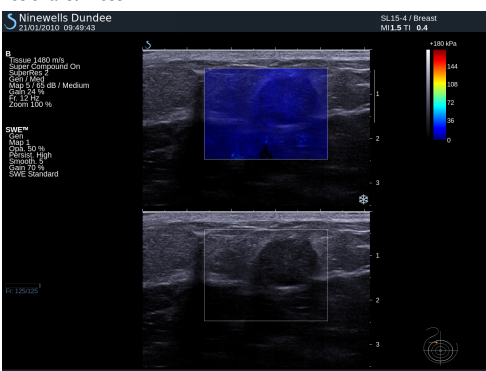
The study group consisted of consecutive patients with solid lesions identified during routine breast scans using the Aixplorer® ultrasound system (SuperSonic Imagine, Aix en Provence, France). Greyscale images were obtained of each solid lesion. These underwent BI-RADS classification by a breast radiologist who was blinded to the elastography findings. BI-RADS categories 1-3 were taken as benign. BI-RADS scores of 4 or 5 were taken as malignant. Two elastography images were obtained of each of the lesions. Twenty women with normal clinical and ultrasound examinations also underwent elastography.

Two independent observers recorded the maximum stiffness, mean stiffness and SD within a ROI placed in the stiffest area within or adjacent to the mass. The average values from the two images were used for analysis. The mean elasticity values from each pair of images were then compared between observers. In 15 cases a second pair of images were acquired by a different observer. After preliminary experience with 10 patients, cut off values for mean elasticity (50 kPa), for maximum elasticity (55 kPa) and for SD (10 kPa) were selected for benign/malignant differentiation on shear wave elastography, as these values were definitive in all 10 cases. Benign/malignant differentiation on greyscale ultrasound with BI-RADS classification and shear wave elastography using the defined cut off values were compared with histology to give figures for sensitivity, specificity, positive and negative predictive values (PPV and NPV) and accuracy. In addition, the area under the ROC curve was calculated for both modalities. Intraclass correlation coefficients using web-based software (sip.medizin.uni-ulm.de) were performed.

ShearWave Elastography image of a cancer showing marked peritumoural stiffness (blue is soft, yellow stiff and red very stiff)



Shearwave Elastography image of a fibroadenoma showing low lesional stiffness



Lay summary

Conventional Ultrasound uses the reflectivity of tissues to create an image. Shearwave elastography allows the stiffness of tissue to be mapped and measured using ultrasound. As cancers tend to be stiff and benign lesions soft this work shows that shearwave elastography can be used to differentiate benign from malignant breast masses. Shearwave elastography appears to be at least as accurate as conventional ultrasound in this task. It also appears to be reproducible.

Results

Fifty-two women with 53 solid breast masses comprised the study group (age range 18-84 yrs, mean 53 yrs). Histology revealed 23 benign lesions and 30 cancers.

Reproducibility

The correlation between measurements by two independent observers of the mean stiffness on each pair of elastography images acquired by a single operator gave an intraclass correlation coefficient of 0.99. The correlation between measurements of the mean stiffness on pairs of elastography images acquired and read by two independent operators gave an intraclass correlation coefficient of 0.80.

Normal tissue

The elastography parameters of the 20 women with normal clinical and ultrasound findings indicated that normal tissue has low mean and maximum stiffness and SD.

Benign lesions

Fibroadenomas show low mean stiffness (average 28 kPa, range 18-44), maximum stiffness and SD values. The four benign lesions with mean stiffness above the 50 kPa threshold were two radial scars, one fat necrosis and one cellular fibroepithelial lesion.

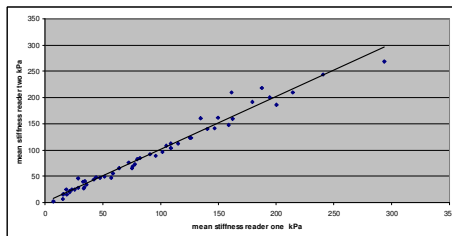
Invasive cancer

Twenty-seven (96%) of the 28 invasive cancers had mean elasticity values above the 50 kPa threshold. The average mean value was 140 kPa (range 29-293).

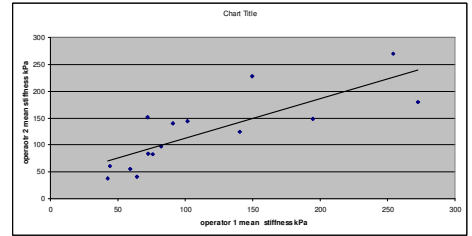
Benign/malignant differentiation

Strong associations were demonstrated between greyscale BI-RADS findings, shear wave elastography findings (mean elasticity, maximum elasticity and SD) and histology ($p < 0.0001$ for all: Fisher's Exact Test). For mean elasticity versus greyscale BI-RADS, the performance results were sensitivity: 97% vs 87%, specificity: 83% vs 78%, PPV: 88% vs 84%, NPV: 95% vs 82% and accuracy: 91% vs 83%. The performance of shear wave elastography outperformed that of greyscale BI-RADS in all standard aspects of performance including the area under the curve on a ROC analysis, however, this difference did not reach statistical significance ($p = 0.129$, Mann-Whitney U-test).

The correlation between measurements by two independent observers of the mean stiffness on each pair of elastography images acquired by a single operator, $r = 0.99$.



The correlation between measurements of the mean stiffness on pairs of elastography images acquired and read by two independent operators gave an intraclass correlation coefficient of 0.80.



Performance results of mean tissue elasticity versus greyscale BI-RADS

	Elastography	BI-RADS
Positive Predictive Value (%; 95% CI)	88 (77-99)	84 (71-97)
Negative Predictive Value (%; 95% CI)	95 (85-100)	82 (66-98)
Sensitivity (True Positive Fraction) (%; 95% CI)	97 (90-100)	87 (75-99)
Specificity (True Negative Fraction) (%; 95% CI)	83 (67-98)	78 (61-95)
Accuracy (%)	91	83
Mis-classification Rate (%)	9	17
Youden's Index	0.79	0.65
Area Under Curve (95% CI)	0.90 (0.81 - 0.98)	0.83 (0.71 - 0.94)
Area Under Curve Difference (95% CI)	0.07 (-0.02 - 0.16)	
p-value (Mann-Whitney U-test)	0.129	

Conclusion

Shear wave elastography gives quantitative and reproducible information on solid breast lesions with diagnostic accuracy at least as good as greyscale ultrasound with BI-RADS classification. After further work, it might be possible to increase the proportion of women with benign masses who can be reassured and discharged based on the ultrasound findings without recourse to ultrasound guided core biopsy.